

COLLATERAL FUNCTION IN PATIENTS WITH CORONARY OCCLUSION EVALUATED BY ²⁰¹THALLIUM SCINTIGRAPHY

AIDA HASANOVIĆ *

Institute of Anatomy, University of Sarajevo, Faculty of Medicine,
Čekaluša 90, 71 000 Sarajevo, Bosnia and Herzegovina

* Corresponding author

ABSTRACT

The present study evaluated the impact of the angiographically documented collaterals on regional myocardial perfusion measured by ²⁰¹thallium scintigraphy in patients with a chronic total occlusion.

The study included 60 patients with chronic total occlusion who underwent rest-stress myocardial perfusion scintigraphy and coronary angiography. All patients had angiographic evidence of coronary collaterals. Patients were divided into two groups: group one had well-developed coronary collateral vessels (n=35) and group II had poor coronary collateral development (n=25).

Patients with chronic total occlusion had severe and extensive stress-induced myocardial perfusion defects regardless of the grade of angiographic coronary collaterals. The perfusion defects in the group with good collaterals were predominantly reversible, suggesting that coronary collaterals preserved myocardial viability in the regions subtended by a total coronary occlusion. A significant correlation between good collaterals with complete protection and poor collaterals with no protection was noted.

Our results demonstrate a protective effect of collaterals on myocardial perfusion during coronary occlusion. The effective angiographic collaterals may prevent resting regional wall motion abnormalities but do not appear to protect against stress-induced perfusion defect.

KEY WORDS: collaterals, myocardial perfusion scintigraphy, chronic total occlusion

INTRODUCTION

The prospective role of coronary collaterals during occlusion of coronary arteries in humans has been debated for years. In infarct patients with angiographically verified collaterals, the extent of myocardial necrosis is smaller compared to patients without collateral supply, evidenced by biochemical and scintigraphic estimates of infarct size, and by less severe regional and global contractile dysfunction (1). Aneurysm formation has been reported to be less frequent in patient with collateral supply to the infarct-related artery (2). The in vivo assessment of collateral function in humans developed from qualitative anatomic evaluation by angiography to physiological assessment by microsensors recording coronary flow velocity and pressure during cardiac catheterization (3,4). Although coronary collaterals have been shown to limit the size of acute myocardial infarction, their ability to protect stress-induced ischemia is uncertain (5). Angiography is used for measuring coronary artery lumen narrowing; however, it is not an ideal method for determining its physiologic significance (6). Myocardial imaging using thallium-²⁰¹ (²⁰¹Tl) is a non-invasive technique which is valuable in the analysis of regional myocardial perfusion. Regions of ischemia caused by severe coronary disease appear as functional defects of tracer accumulation in the myocardial scintigram (7,8). Using ²⁰¹Tl imaging, we have analyzed the role of coronary collateral circulation in the preservation of regional myocardial perfusion during coronary occlusion and have identified the angiographic features of collateral vessels responsible for such protection.

PATIENTS AND METHODS

Sixty patients with coronary artery disease angiographically documented at the Department of Nuclear Medicine were investigated by (²⁰¹Tl) myocardial scintigraphy between January 2005 and May 2007, shortly after coronary artery disease had been demonstrated by contrast arteriography. All patients selected for myocardial imaging had severe stenosis or total occlusion of at least one major coronary artery. The majority of patients had complete occlusion of at least one vessel. Significant coronary stenosis is defined as a reduction in coronary lumen by more than 50 percent, and severe stenosis as a reduction in diameter greater than 80 percent. Patients with hypertension, valvular heart disease, or primary myocardial disease were excluded from this study.

The study was approved by the local ethical committee and conducted in accordance with the Helsinki declaration.

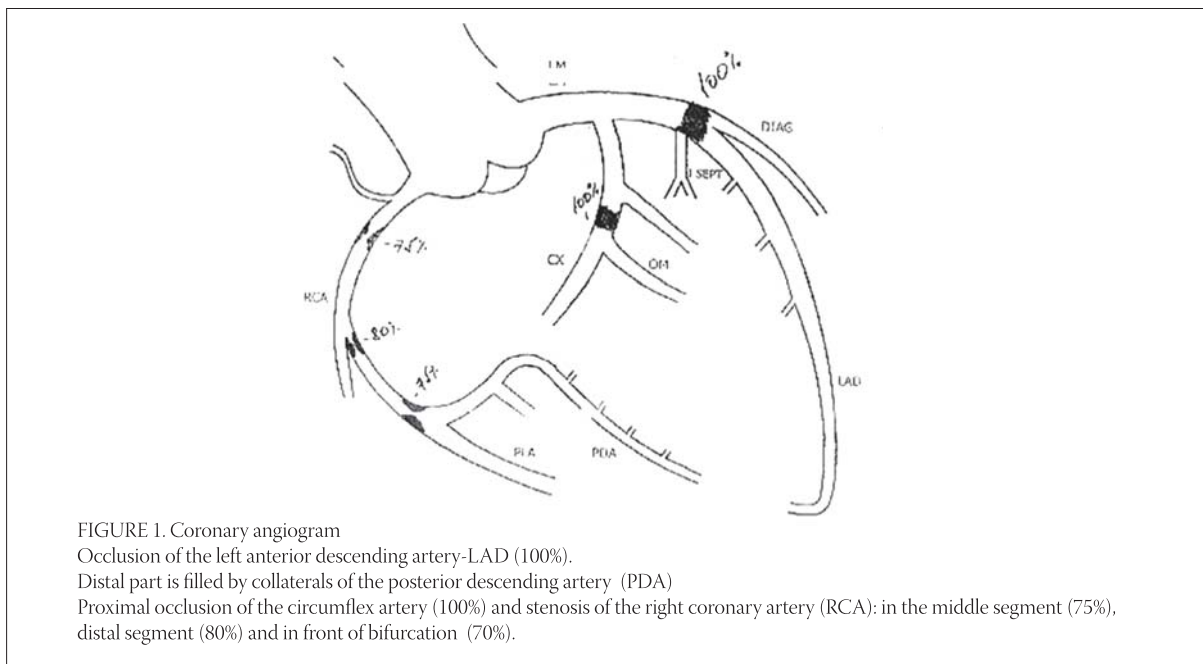
Angiography analysis

Selective coronary angiography was performed in multiple projections using the Judkins technique. All coronary arteriograms were reviewed independently by two observers ignorant of the scintigraphic analysis, and note was made of the position and number of complete coronary occlusions and severe coronary stenoses together with any associated coronary collateral channels. We determined maximal lumen constriction of the coronary artery (right coronary artery-RCA, left anterior descending artery-LAD, and circumflex artery-Cx). We established anatomical variations of coronary circulation classified as right, left or balanced type, and the existence, origin and the direction of collaterals. We graded collaterals in the angiograms as "adequate" (average caliber greater than 1,0 mm) and "inadequate" (average caliber -1 mm and less). For all patients, we applied left ventriculography for the evaluation of left ventricle function, ejective fraction and kinetics. Left ventriculography was performed in the right anterior oblique projection.

Scintigraphy

Studies of regional myocardial perfusion were performed at rest and under exertion (maximal exercise test on a bicycle ergometer). All patients had a complete physical examination, resting 12 lead electrocardiogram, and an electrocardiogram recorded during maximal exercise test on a Monark bicycle ergometer with lead V5 monitoring. During the exercise test each patients received 1,5 mCi of ²⁰¹Tl through an indwelling intravenous cannula at the onset of angina pectoris or limiting dyspnoea. The exercise end-point was maintained for one and a half to two minutes so that myocardial uptake of circulating tracer was maximal in the presence of symptoms. After 10-minute recovery period, myocardial imaging was performed with subjects in the supine positions using a gamma camera and a high-sensitivity parallel-holed collimator.

Anterior, left anterior oblique 45° and 70° were routinely acquired in every patient (each position-five minutes) after exercise and repeated after 3 hours of redistribution. We applied 20 % symmetric energy window centered on the 72 keV peak. All projections' images were stored on magneto-optic disks in a 64x64 matrix. The digital images were displayed



on a TV monitor. After computer processing, digital scintigraphic images were described by one interpreter. Localization of perfusion defects in relation to corresponding blood vessel was determined visually in each image divided into five segments. Each defect was further classified as moderate or severe according to the degree of tracer deficit seen in that region. The result was considered "positive" when a reversible defect was assigned to the perfusion territory of the coronary artery of interest. Defects located in the anterior wall and septal region were assigned to the left anterior descending artery, defects in the lateral wall were assigned to the left circumflex coronary artery, and defects in the inferior wall were assigned to the right coronary artery. Statistical comparison of data was performed using Chi-square test. Using Chi-square test, the differences between the groups were considered significant when $P < 0,001$.

RESULTS

The study included 60 patients with chronic total occlusion who underwent rest-stress myocardial perfusion and coronary angiography. All patients had angiographic evidence of coronary collaterals. Thirty-five patients had angiographically well-developed coronary collateral vessels (Figure 1), while twenty five had poor coronary collateral development. In the first group, regional left ventricular function was predominantly normal or hypokinetic. In the group with poor collaterals in the vast majority of cases akinesia or dyskinesia of the corresponding myocardial segment was demonstrated. The difference between the two groups was significant at 0,001 level. Ejection fraction in the group with

well-developed coronary collateral vessels and good left ventricular function was $> 50\%$; in the group with inadequate collateral circulation it was 35%. Our patients with chronic total occlusion had severe and extensive stress-induced myocardial perfusion defects regardless of the grade of angiographic coronary collaterals. Perfusion defects in the group with good collaterals were predominantly reversible (Figure 2.), suggesting that well-developed coronary collaterals preserved myocardial viability in the regions subtended by a total coronary occlusion. In the group with poor coronary collateral development perfusion defects were predominantly irreversible.

The relation between the degree of coronary collateral development assessed angiographically and the severity of ²⁰¹Tl uptake defects seen in the myocardial scintigram showed highly significant association between well-developed coronary collateral vessels and accompanying preservation of myocardial ²⁰¹Tl uptake. Similarly, poor or absent coronary collateral development was usually associated with severe deficit of tracer in corresponding regions of the scintigram. Angiographically invisible collaterals were never associated with complete scintigraphic protection and usually conferred no protective benefit. Similarly, vessel ghosting was always accompanied by severe scintigraphic uptake defects. Bridging collaterals also offered inadequate protection from myocardial ischemia during exercise. Our results demonstrate that the effective angiographic collaterals may prevent resting regional wall motion abnormalities but do not appear to protect against stress-induced perfusion defect.

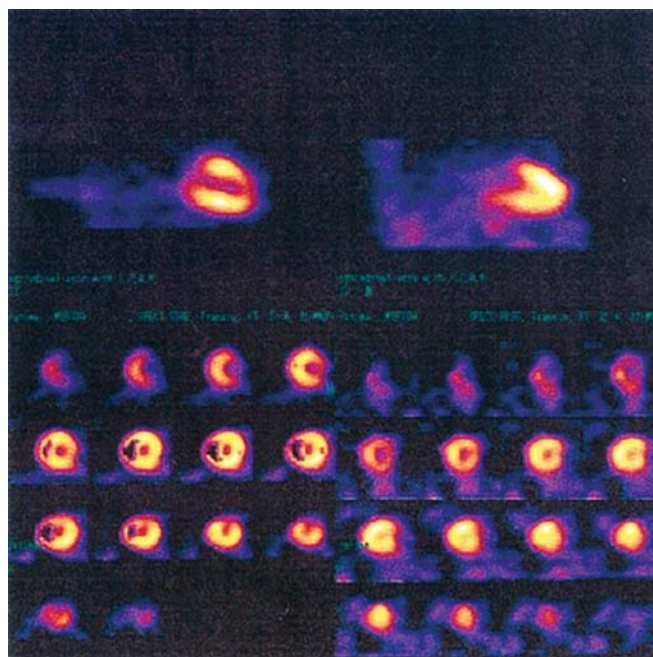


FIGURE 2. Single-photon emission tomography of the heart with ²⁰¹thallium was performed according to the standard stress (planar projection-45°); Analysis of perfusion scintigrams in patients with angiographically documented collaterals suggest reversible defect of antero-apical segment, and ischemia of this region

DISCUSSION

In patients with chronic total occlusion, our study investigated the relationship between the angiographic development of collateral circulation, rest and stress myocardial perfusion scintigraphy variables, and regional wall motion abnormalities. Patients with chronic total occlusion had severe and extensive stress-induced myocardial perfusion defects regardless of the grade of angiographic coronary collaterals. Several studies have suggested that coronary collaterals preserve resting myocardial flow but are inadequate to protect against reduced blood flow during hyperemic stress (1,2). In contrast, several studies with planar ²⁰¹Tl scintigraphy suggested that coronary collaterals also prevent stress-induced ischemia (3,4). Our study showed that the perfusion defects in the group with good collaterals were predominantly reversible, suggesting that well-developed coronary collaterals preserved myocardial viability in the regions subtended by a total coronary occlusion. Our results demonstrate that the effective angiographic collaterals may prevent resting regional wall motion abnormalities but do not appear to protect against stress-induced perfusion defect. The relation between the degree of coronary collateral development assessed angiographically and the sever-

ity of ²⁰¹Tl uptake defects seen in the myocardial scintigram in our patients showed a association between well-developed coronary collateral vessels and accompanying preservation of myocardial ²⁰¹Tl uptake. Using ²⁰¹Tl myocardial scintigraphy many patients with total occlusive disease of dominant right coronary artery are seen to have adequate collateral vessels providing complete protection from ischemia in the distribution of this artery during dynamic exercise. Patients with left anterior descending disease, however, were not protected from the occurrence of ischaemic uptake defects (5,6) Although the mechanism of this protection is not clear, normal pressure gradient that exists between left and right ventricles may be increased during dynamic exercise, particularly during diastole in an ischaemic left ventricle, so that collateral flow is maintained or increased in the direction of the low pressure in right ventricular myocardium. This effect probably accounts for the preservation of tracer uptake in the inferior wall of the left ventricle as seen in ²⁰¹Tl scintigrams (1,7,8) However, one relevant limitation of ²⁰¹Tl imaging is that relative regional myocardial ischaemia is reflected in the scintigram rather than in terms of absolute perfusion. Thus, it is possible that even though the right coronary artery territory is ischemic during exercise, it is better perfused than the left coronary artery.

CONCLUSION

1. The clear correlation between the angiographic grade of collaterals and corresponding areas of protection seen in the scintigram gives the angiographer reasonable reassurance that there is functional relevance in detailed description of these important channels.
2. ²⁰¹Tl scintigraphy provides a functional map of the myocardium in terms of patterns of ischemia and thus allows for functional interpretation of corresponding anatomy seen in the coronary angiogram.
3. In patients with occlusion, coronary collaterals appear to protect against resting perfusion defects. Excellent angiographic collaterals may prevent resting regional wall motion abnormalities but do not appear to protect against stress-induced perfusion defects.

REFERENCES

- (1) Wainwright R.J., Maisey M.N., Edwards A.C., Sowton E. Functional significance of collateral circulation during dynamic exercise evaluated by thallium-²⁰¹ myocardial scintigraphy. *Br. Heart J.* 1980;47:55.
- (2) Aboul-Enein F., Kar S., Hayes S.W., Sciammarella M., Abidov A., Makkar R., Friedman J.D. et al. Influence of angiographic collateral circulation on myocardial perfusion in patients with chronic total occlusion of a single coronary artery and no prior myocardial infarction. *J. Nucl. Med.* 2004;45(6):950-955.
- (3) Sand N.P., Rehling M., Bagger J.P., Thuesen L., Flo C., Nielsen T.T. Functional significance of recruitable collaterals during temporary coronary occlusion evaluated by ^{99m}Tc-sestamibi single-photon emission computerized tomography. *J. Am. Coll. Cardiol.* 2000;35:624-632.
- (4) Werner G.S., Ferrari M., Betge S., Gastmann O., Richartz B.M., Figulla H.R. Collateral function in chronic total coronary occlusions is related to regional myocardial function and duration of occlusion. *Circulation.* 2001;104:2784-2790.
- (5) Holmvang G., Fry S., Skopicki H.A., Abraham S.A., Alpert N.M., Fischman A.J. et al. Relation between coronary „steal“ and contractile function at rest in collateral-dependent myocardium of humans with ischemic heart disease. *Circulation.* 1999;99:2510-2516.
- (6) Tajfl D., Kamenica S., Spaić R., Milošević A., Odavić M. Uticaj kolateralnog srčanog krvotoka na rezultate scintigrafije srčanog mišića u bolesnika sa ishemijskom bolešću srca. *Vojnosanit. Pregled* 1987; 44 (2) : 128-131.
- (7) Hasanović A., Kulenović A., Šišić F. The role of collateral circulation in preserving myocardial function. *Bosn. J. Basic Med. Sci.* 2006;6(4):29-31.
- (8) Hasanović A., Jurić I., Fazlibegović E. Perfuziona scintigrafija miokarda i ehokardiografija kod pacijenata sa koronarnim kolateralama. *Medic. Žurn.* 2002; 8 (1):12-17.