



CORRELATION BETWEEN REFRACTION LEVEL AND RETINAL BREAKS IN MYOPIC EYE

EMINA ALIMANOVIĆ-HALILOVIĆ*

Eye Clinic, University of Sarajevo Clinics Centre,
Bolnička 25, 71000 Sarajevo, Bosnia and Herzegovina

* Corresponding author

ABSTRACT

In this study we analyzed 180 myopic eyes in order to determine the refraction that is “critical” for the occurrence of retinal breaks as a main cause of retinal detachment. Detachment of retina involves separation of the neurosensory retina from the pigmented epithelium with the severe impairment of vision. After the focused ophthalmological assessment, determination of objective refraction, indirect binocular ophthalmoscopy, we compared the diagnosed retinal breaks according to the shape with the refraction. All the examined eyes were divided into six groups according to the axis length. Mean age of our patients was between 48,43 and 51,60 years with SD ranging from 13,88 to 18,45. The age differences among the groups were not statistically significant. This study included 102 (56,7%) male and 78 (43,3%) female patients and no statistically significant differences between genders was found regarding the occurrence of retinal breaks compared to refraction. The most dominant ruptures were the round ones (28,2%), followed by oval (25%), the category of multiple small holes (19,2%), horseshoe shaped (15,3%), and finally holes with operculum. In cases with myopic refraction ranging between 3,50 and 7,49 dsph, the frequency of retinal breaks statistically significantly differs from all other analyzed refractions. Also, there is positive correlation between the above mentioned myopic refraction and the frequency of retinal breaks.

In order to prevent retinal detachment in a myopic eye, we suggest further thorough examinations of the eye fundus in patients with the above mentioned myopia. Diagnosing retinal breaks involves the application of adequate therapy: laser photocoagulation, cryotherapy, sclera buckling and pneumatic retinopexy.

KEY WORDS: myopia, “critical” refraction, retinal breaks

INTRODUCTION

On a daily basis, ophthalmologists witness retinal detachment in people with different myopic refraction. Detachment of retina involves separation of the neurosensory retina from the pigmented retinal epithelium and it is one of emergency conditions in ophthalmology. Many researches demonstrated that peripheral retinal degenerations, retinal tears, vitreoretinal tractions and detachment of vitreous cavity play an important role in the pathogenesis of retinal detachment (1, 2). Also, 42% of retinal detachment cases are associated with myopic refraction (3). Prevalence of myopic refraction among adults in the USA is 20 %, in Western European countries 26,6%, the UK 53,6%, and in Australia 77% (4, 5, 6). Timely detection of predisposing lesions and retinal tears, as well as the application of adequate prophylactic measures play an important role in the prevention of retinal detachment (7). Retinal tears are breaks in the retina continuity which affect all layers except the pigmented epithelia. The existence of retinal tears was first noticed by Helmholtz, while Gonin pointed out the importance of their surgical closing in order to treat retinal detachment (8). In morphological sense, we may distinguish horseshoe-shaped breaks, breaks with operculum, round or oval ones, U-shaped ruptures, and incomplete or layered erosions. Desinsertio s. dialysis retinae represent a special shape of retinal tears when the retina separates in the area of ora serata (9). The main goal of this research was to establish "critical myopic refraction" where the largest number of retinal breaks is found as a direct cause of retinal detachment.

PATIENTS AND METHODS

The study was conducted as clinical, prospective, and controlled. We analyzed 180 eyes of patients with myopia. The study included all the patients with myopia of 0,25 dsph or more verified by ophthalmological methods of examination regardless of gender, profession and stage of disease, The patients with acute ophthalmological conditions and other diseases which cause non-transparency in optical mediums were excluded from the study. After personal ophthalmological anamnesis with a special focus on the visual acuity and symptoms ("a flying fly", "scintillae" and the occurrence of "curtain" within the field of vision), we analyzed family history in terms of positive anamnesis in closest relatives. Afterwards, we measured the objective refraction using computerized refractometry in midriasis. The examination

of chorioretina was performed by indirect binocular biomicroscopy using the Volk lens of 90 dsph and the Goldmann contact prism. All the observed changes were noted on the Amsler-Dubois scheme, modified according to Schepens, which included the area of ora serata, using the Meyer-Schwickerath symbols. Concerning the elements of vital statistics, we analyzed the sample according to gender and age. In cases of parametric values, we used Student t-test, while Chi-square test was used for nonparametric data. According to the refraction value, all eyes were divided into six groups:

- 1) from 0,25 to 1,99 dsph,
- 2) from 2,00 to 3,49 dsph,
- 3) from 3,50 to 7,49 dsph,
- 4) from 7,50 to 12,49 dsph,
- 5) from 12,50 to 19,99 dsph,
- 6) from 20,00 to 30,00 dsph.

RESULTS

The patients' age was compared against the value of refraction. Mean age of our patients was within range from 48,43 to 51,60 with SD ranging from 13,88 to 18,45 (Table 1).

Dsph	-0,25	-2,00	-3,50	-7,50	-12,50	-20,00
	-1,99	-3,49	-7,49	-12,49	-19,99	-30,00
	I	II	III	IV	V	VI
N	30,00	30,00	30,00	30,00	30,00	30,00
X	49,13	48,43	51,00	51,60	48,70	50,40
SD	16,84	14,86	15,51	18,45	16,34	13,88

TABLE 1. Patients' age compared against refraction

In the cases of myopia from 7,5 to 12,5 dsph the group included patients of advanced age. Also, the group with myopia ranging from 2,0 to 3,5 dsph included young ones. However, these differences were not statistically significant.

Dsph	-0,25		-2,00		-3,50		-7,50		-12,5		-20,00	
	-1,99		-3,49		-7,49		-12,49		-19,99		-30,00	
	I		II		III		IV		V		VI	
	f	%	f	%	f	%	f	%	f	%	f	%
MALES	19	63,3	16	53,3	22	73,3	14	46,7	15	50,0	16	53,3
FEMALES	11	36,7	14	46,7	8	26,7	16	53,3	15	50,0	14	46,7

TABLE 2. Distribution of patients according to gender compared to the refraction values

Distribution of patients according to gender compared to the refraction values is presented in Table 2. We did not find any statistically significant differences in the gender-related occurrence of retinal breaks compared to the refraction. We analyzed retinal breaks according to the shape at the equator-ora serata location compared

to the refraction values. According to shape, we divided them into: round, oval, horseshoe shaped, breaks with operculum and the category of multiple small holes.

Dsph	-0,25		-2,00		-3,50		-7,50		-12,5		-20,00	
	-1,99		-3,49		-7,49		-12,49		-19,99		-30,00	
	I		II		III		IV		V		VI	
	f	%	f	%	f	%	f	%	f	%	f	%
ABSENT	22	73,33	18	60,00	10	33,33	15	50,00	17	56,68	18	60,00
ROUND	4	13,33	5	16,66	5	16,66	3	10,00	2	6,66	3	10,00
OVAL	1	3,33	2	6,68	3	10,00	4	13,33	3	10,00	7	23,33
HORSE-SHOE	1	3,33	0	0,00	7	23,33	3	10,00	3	10,00	0	0,00
WITH OPERC.	0	0,00	1	3,33	3	10,00	1	3,33	3	10,00	1	3,33
MULTIPLE SMALL	2	6,68	4	13,33	2	6,68	4	13,33	2	6,66	1	3,33

TABLE 3. Distribution of peripheral retinal breaks according to shape compared to the refraction

According to the data in Table 3. we found 78 (43,3%) retinal breaks in the total of 180 tested eyes, while no breaks were observed in 102 (56,7%) cases.

Dsph	0,25	-2,00	-3,50	-7,50	-12,50	-20,00
	-1,99	-3,49	-7,49	-12,49	-19,99	-30,00
-0,25		p=0,6217	p=0,0098 *	p=0,3127	p=0,2774	p=0,1941
-1,99						
-2,00			p=0,0115 *	p=0,4880	p=0,2890	p=0,4064
-3,49						
-3,50				p=0,3177	p=0,3456	p=0,0060 *
-7,49						
-7,50				p=0,8302	p=0,3169	
-12,49						
-12,50					p=0,2907	
-19,99						

TABLE 4. Results of Chi-square test $\alpha=0.05$ (*fields in orange represent significance) related to Table

DISCUSSION

Retinal breaks in myopic patients' eyes are a huge risk for the occurrence of retinal detachment, which results in the decrease of vision and damage to other functions of sight. Retinal breaks may vary in shape and location. In the cases of diagnosed retinal breaks in one eye, it is recommended to also test the other, "healthy eye". Bilateral retinal tears are often combined with their symmetric localization. The breaks can be located in various sectors and meridians of the fundus, including the macula (10, 11). However, the upper temporal quadrant is considered to be the most frequent location of retinal breaks

in general, 67% according to Evertt and 55% according to Tulloh (12, 13). In this study, we analyzed the occurrence of retinal breaks in various myopic refractions. Mean age of our patients varied from 48,43 to 51,60 with SD ranging from 13,88 to 18,45. After in-group analyses of retinal break frequency according to patient's age, we did not find any statistically significant difference, but we could establish that in the group with myopia ranging between 7,5 and 12,5 dsph, we found older patients, and younger ones in the group with myopia ranging from 2,0 to 3,5 dsph (Table 1). Michels noticed in his study that myopia-related retinal detachments occur in younger population, and that they are combined with retinal tears and degenerations. Blagojević, on the other hand, in his sample, found that the most frequent age for the retinal detachment was the 40s (15). This study included 102 (56,7%) male and 78 (43,3%) female patients. The inter-group analysis by Chi-square test did not establish any statistically significant differences regarding the occurrence of retinal breaks between genders compared to refraction. However, we could still establish that the majority of males had myopia ranging from 3,5 to 7,49 dsph, while females had cases of myopia from 7,5 to 12,49 dsph (Table 2). In our patients, we found 78 (43,3%) retinal ruptures located in the area of the equator-ora serata in different quadrants, most often in the upper temporal one. We analyzed those retinal ruptures according to shape. The most frequent were round (28,2%), then oval ones (25%), the category of multiple smaller ruptures (19,2%) and horseshoe-shaped ones (15,3%), and finally ruptures with operculum. As retinal ruptures have a direct impact on the occurrence of retinal ablation, we tried to detect the "critical" myopic refraction with the largest frequency. The frequency of retinal ruptures was 20 in the third group, then 15 in the fourth, 13 in the fifth, and so on (Table 3). We found statistically significant difference between the first and the third groups with $p=0,0098$, and $\alpha=0,05$, between the second and the third with $p=0,00115$, and between the third and the sixth with $p=0,0060$. In case of myopic refraction from 3,5 to 7,49 dsph, the frequency of ruptures statistically significantly differs from all other refractions (Table 4). Statistical results allow us to conclude that there is a positive correlation between the mentioned myopic refraction and the frequency of retinal breaks. The occurrence of retinal breaks in myopic eye must be taken seriously. Patients usually complain of metamorphops, micropsy, glittering in front of the eye and opacities. In some cases, retinal tears are "silent";

they pass undetected, and they are discovered during routine examinations. Retinal breaks with edges without vitreoretinal tractions do not require preventive treatment (16). Nevertheless, in cases of myopic, phakic and pseudophakic eyes, in persons who actively practice sport, in patient with positive family history or similar changes in the other eye, it is recommended to close the breaks. In order to prevent the retinal detachment (16), the following methods can be applied: laser photocoagulation, cryotherapy, scleral buckling, or pneumatic retinopexy. (17, 18). (Figure 1) After these interventions, complications can occur, such as macular pucker in 0 to 2,2 %, degeneration of vitreous cavity in 2,1 to 6,7% and retina detachment in 1,8 to 6,2% cases (18, 19).

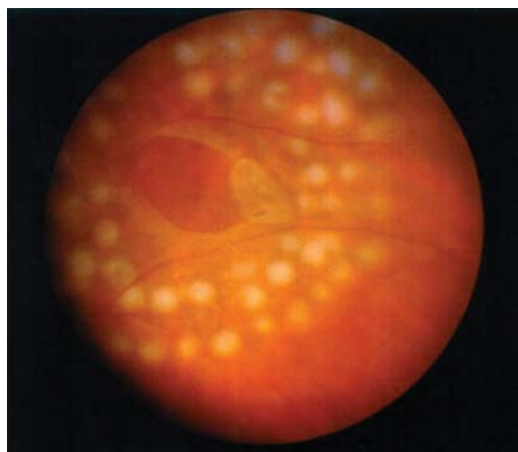


FIGURE 1. Retinal break - Laser photocoagulation

CONCLUSION

Myopic refraction ranging from 3,5 to 7,49 dsph can be considered as "critical" for the occurrence of retinal breaks, and then of the retinal detachment as well.

In order to prevent the retinal detachment in the eye with myopia, we suggest a detailed examination of patients with draws refractions. Diagnosed retinal breaks can be adequately surgically treated as prevention.

REFERENCES

- (1) Akyol N., Kukner A.S., Ozdemir T., Esmerligil S. Choroidal and retinal blood flow changes in degenerative myopia. *Canadian J. Ophthalmol.* 1996;31(3):113-119.
- (2) Ghazi N.G., Green W.R. Pathology and pathogenesis of retinal detachment. *Eye*, 2002;16(4):411-421
- (3) Burton T.C. The influence of refractive error and lattice degeneration on the incidence of retinal detachment, From the Eye institute, Wisconsin, Tr. Am. Ophth. 1989: 143-157.
- (4) Logan N.S., Davies L.N., Mallen E.A., Gilmartin B. Ametropia and ocular biometry in a UK university student population. *Optom. Vis. Sci.* 2005;82(4):261-266.
- (5) Wensor M., McCarty C.A., Taylor H.R. Prevalence and risk factors of myopia in Victoria, Australia. *Arch. Ophthalmol.* 1999; 117(5):658-663.
- (6) Kempen J.H., Mitchell P., Lee K.E., Tielsch J.M., Broman A.T., Taylor H.R., Ikram M.K., Congdon N.G., O'Colmain B.J. Eye Diseases Prevalence Research Group. The prevalence of refractive errors among adults in the United States, Western Europe, and Australia. *Arch. Ophthalmol.* 2004; 122(4):495-505.
- (7) Mastropasqua L., Carpineto P., Ciancaglini M., Falconio G., Gallega P.E. Treatment of retinal tears and lattice degenerations in fellow eyes in high risk patients suffering retinal detachment: a prospective study. *Br. J. Ophthalmol.* 1999; 83(9):1046-1049.
- (8) Gonin J., Helmholtz I. In Blagojević M. Clinical characteristics of retinal detachment, Retinal detachment, surgical therapy, prevention. Eye Clinic "Đorđe Nešić PhD MD". Beograd, 1976: 79-92.
- (9) Kanski J. Clinical Ophthalmology. Patogenesis of retinal detachment. Oxford: Butterworth, Heinemann LTD, 1994; 317-328.
- (10) Katušić D., Klinger M., Šikić J., Kordić R. The find of the other eye in case of retinal detachment regmatogenes. *JOA.* 1986;24(3-4):193-195.
- (11) Peyman A.G., Schulman A.J. Vitreous changes in myopia. *Intravitreal surgery Principles and Practice.* Prentice-Hall International Inc., Appleton & Lange USA, 1994; pp. 29-31
- (12) Everett W.G. In: Blagojević M. Clinical characteristics of retinal detachment, Retinal detachment, surgical therapy, prevention. Eye Clinic "Đorđe Nešić PhD MD". Beograd, 1976: 79-92.
- (13) Tulloh N. In Blagojević M.: Clinical characteristics of retinal detachment, Retinal detachment, surgical therapy, prevention. Eye Clinic "Đorđe Nešić PhD MD". Beograd, 1976: 79-92.
- (14) Michels R.G., Wilkinson C.P., Rice T.A. Retinal detachment. Prevention of retinal detachment. 1990:1093-1107.
- (15) Blagojević M. Clinical characteristics of retinal detachment, Retinal detachment, surgical therapy, prevention. Eye Clinic "Đorđe Nešić PhD MD". Beograd, 1976: 79-92.
- (16) American Academy of Ophthalmology. Preferred practice pattern: Retinal detachment. San Francisco: AAO.1990.
- (17) Pierro I., Camesasca FJ., Mischi M., Brancato R. Peripheral retinal changes and axial myopia. *Retina*, 1992; 12:12-17.
- (18) Jones W.L., Cavallerano A. A., Margan K.M., Semes L.P., Sherman J.F., Vandervort R.S., Wooldridge R.P. Optometric clinical practice guideline care of the patient with retinal detachment and related peripheral vitreoretinal disease. AOA. U.S.A. St. Louis, 1995, reviewed 2004.
- (19) Meyer-Schwickerath G., Frider M. Prophylaxis of retinal detachment. *Trans Ophthalmol. Sc.* Clinical characteristics of retinal detachment, Retinal detachment, surgical therapy, prevention. Eye Clinic "Đorđe Nešić PhD MD". Beograd UK 1980; 100: 56-65.