

DOPPLER SONOGRAPHY CHARACTERISTICS OF VERTEBROBASILAR CIRCULATION IN PATIENTS WITH PARKINSON'S DISEASE

MIRJANA VIDOVIĆ*, OSMAN SINANOVIĆ, DŽEVDET SMAJLOVIĆ,
ADNAN BURINA, JOSIP HUDIĆ

Department of Neurology, University Clinical Centre Tuzla, Faculty of Medicine,
University of Tuzla, Trnovac bb, 75 000 Tuzla, Bosnia and Herzegovina

* Corresponding author

ABSTRACT

The objective of the study was to analyze the doppler sonography findings of vertebrobasilar circulation (VB) in patients with Parkinson's disease. 40 patients were analyzed (25 men's and 15 women) with Parkinson's disease, average age was 61,9 years (SD=11,43), treated at the Clinic for Neurology in Tuzla. Device for doppler sonography was Multidop x 4. Doppler sonography findings of VB circulation were analyzed in order to computerized tomography (CT) findings of the brain (with or without ischemic lacunar lesions) and in order to presence of postural disturbances as one of dominant Parkinson's disease symptoms during actual hospitalization. Our results suggest that vertebrobasilar insufficiency is more frequent in patients with Parkinson's disease (no matter of type) and postural disturbances as a dominant symptom comparing to group of Parkinson's disease patients without postural disturbances. These results implicate the importance of doppler sonography findings of vertebrobasilar circulation in patients with Parkinson's disease and possibility of considering role of vertebrobasilar insufficiency in development of postural disturbances.

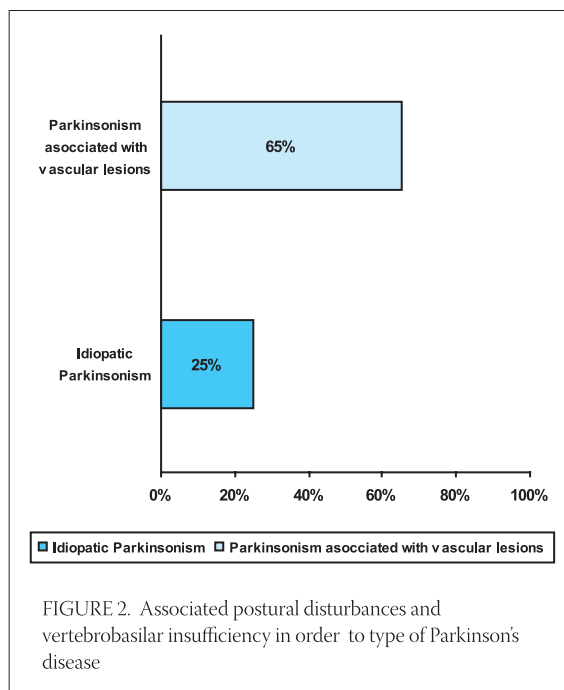
KEY WORDS: Parkinson's disease, Doppler sonography

INTRODUCTION

Parkinson's disease is neurodegenerative disease leading to patients inability, which is primarily caused by cells loss containing dopamine in substantia nigra, decreasing dopamine concentration in striatum as well (1). In USA more then million people have this disease and incidence is getting higher with extending human life (2). Characteristics of this disease are tremor, rigor, posture disorder and bradicinesia, slowly and constantly deteriorating over the years (3,4). The objective of the study was to analyze doppler sonography findings of vertebrobasilar circulation (VB) in patients with Parkinson's disease.

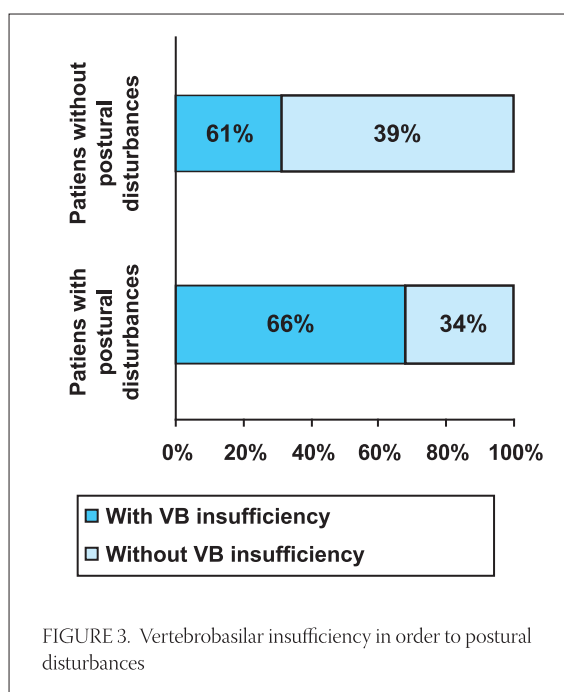
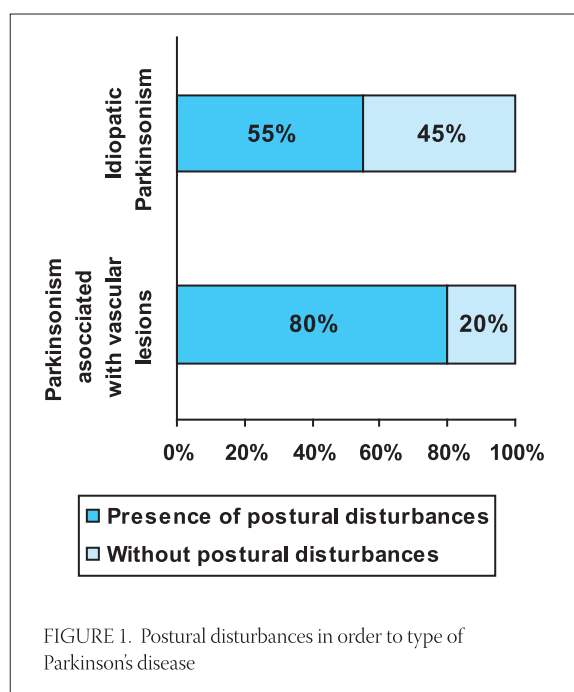
PATIENTS AND METHODS

Forty patients (25 men's and 15 women) with Parkinson's disease were analyzed, average age of 61,9 years (SD=11,43), treated at the Clinic for neurology in Tuzla. Device for doppler sonography was Multidop x 4. The lower physiological values limits were: the average speed blood flow of 32 cm/s in basilar and 27cm/s in both vertebral arteries. VB circulation was analyzed both in order to computerized tomography (CT) findings of the brain (with or without ischemic lacunar lesions) and presence of postural disturbances as one of dominant Parkinson's disease symptoms during actual hospitalization. For statistical evaluation it was used standard statistical parameters: mean value, percentage, χ^2 test.



RESULTS

In this study postural disturbances as a dominant symptom was more frequent noticed in group of patients with Parkinson's disease associated with vascular lesions (16/20; 80%) in order to group with idiopathic Parkinson's disease (11/20; 55%) (Figure 1). Associated postural disturbances and verified VB insufficiency is significantly higher ($p=0,02$) in first group (13/20, 65%) in order to second group (5/20; 25%) of patients (Figure 2).



VB insufficiency, verified by doppler sonography, in patients with Parkinson's disease (no matter of type) and postural disturbances as a dominant symptom (n=27), was presented in 18 patients (66%) what was significantly different (p=0,03) in order to group of patients without postural disturbances (n=13) where VB insufficiency was verified in 4 patients (31%) (Figure 3).

DISCUSSION

Postural disorder generate walking disturbance, reducing mobility and can provoke patients injuries. This is leading symptom in loss of functional independency and social isolation of patients (5). In this study postural disturbances as a dominant symptom was more frequent in group of patients with Parkinson's disease associated with vascular lesions in order to group with idiopathic Parkinson's disease. Other authors reported that postural instability, "freezing" phenomenon, gait disturbance, pyramidal signs, and postural tremor

were significantly more frequent in patients with Parkinson's disease associated with vascular lesions than in patients with idiopathic Parkinson's disease (6). Verified VB insufficiency associated with postural disturbances is significantly more frequent in first group as well. Vertebrobasilar insufficiency, verified by doppler sonography, in patients with Parkinson's disease (no matter of type) and postural disturbances as a dominant symptom (n=27), was presented in 66% of patients in order to group of patients without postural disturbances where VB insufficiency was verified in 31% of patients. Diagnosis of Parkinson's disease is based on clinical signs, symptoms and responds to therapy which is goal reduction in degeneration of dopamine neurons, the main pathophysiological disorder in Parkinson's disease (3). There is no specific diagnostic test for Parkinson's disease. Results of this study refer that in patients with dominant postural disturbances, beside usual tests (laboratory tests, CT of the brain or nuclear magnetic resonance) also it is necessary to evaluate a vertebrobasilar circulation.

CONCLUSION

Doppler sonography of vertebrobasilar circulation in Parkinson's disease patients might become important test and open possibility of vertebrobasilar insufficiency impact on development of postural disturbances.

REFERENCES

- (1) Asanuma K., Dhawan V., Carbon M., Eidelberg D. Assessment of disease progression in parkinsonism. *J. Neurol.* 2004; 251 (suppl 7): 4-5.
- (2) Schapira A.H.V. and Olanow C.W. Neuroprotection in Parkinson disease: Mysteries, myths and misconceptions. *JAMA* 2004; 291: 358-364.
- (3) Seibyl J., Jennings D., Tabamo R., Marek K. Neuroimaging trials of Parkinson's disease progression. *J. Neurol.* 2004; 251 (suppl 7): 9-13.
- (4) Schlossmacher M.G, Sudarsky L.R. Parkinson's disease. In *Best Practice of Medicine*. <http://praxis.md/bpm/bpmviewwall.asp?page=BPM01NE11> [accessed:10.01.2001.]
- (5) Bronte-Stewart H.M., Minn Y., Rodrigues K., Buckley E.L., Nashner L.M. Postural instability in Idiopathic Parkinson's disease: The role of medication and unilateral pallidotomy. *Brain* 2002; 125 (Pt 9): 2100-2114.
- (6) Demirkiran M., Bozdemir H., Sarica Y. Vascular parkinsonism: a distinct, heterogeneous clinical entity. *Acta Neurol. Scand.* 2001;104(2): 63-67.