

# PHOTOPERIODISM AS A MODIFIER OF EFFECT OF EXTREMELY LOW-FREQUENCY ELECTROMAGNETIC FIELD ON MORPHOLOGICAL PROPERTIES OF PINEAL GLAND

TAMARA LUKAČ<sup>1\*</sup>, AMELA MATAVULJ<sup>2</sup>,  
MILICA MATAVULJ<sup>3</sup>, VESNA RAJKOVIĆ<sup>3</sup>, BOGOSAV LAŽETIĆ<sup>4</sup>

1. Institute of Physical Medicine, Rehabilitation and Balneoclimatology Mlječanica, 79247 Međuvode, Kozarska Dubica/Bosanska Dubica, Bosnia and Herzegovina
2. Institute of Physiology, Faculty of Medicine, University of Banja Luka, Save Mrkalja 14, 78000 Banja Luka, Bosnia and Herzegovina
3. Department of Biology, Faculty of Sciences, Trg Dositaja Obradovića 2, 21000 Novi Sad, Serbia
4. Institute of Physiology, Faculty of Medicine, Hajduk Veljkova 3, 21000 Novi Sad, Serbia

\* Corresponding author

## ABSTRACT

The aim of our study was to determine, using histological and stereological methods, whether photoperiodism has any impact on the effects that chronic (three-month long) exposure to LF-EMF (50Hz) has on morphological characteristics on rat's pineal gland. The experiment was performed on 48 Mill Hill male rats (24 experimental and 24 control). Upon birth, 24 rats were exposed for 7h a day, 5 days a week for 3 months to LF-EMF (50 Hz, 50-500 $\mu$ T, 10V/m). In the winter (short days, long nights), the activity of the pineal gland and neuroendocrine sensitivity is increased. The study was performed both during summer and winter, following the identical protocol. After sacrifice of animals, samples of pineal gland were processed for HE staining and then were analyzed using the methods of stereology. The most significant changes in epiphysis in the first group of animals in wintertime are: altered glandular feature, hyperemia, reduced pinealocytes with pale pink, poor cytoplasm and irregular, stick-form nuclei. In the second group (II) pinealocytes are enlarged, with vacuolated cytoplasm and hyperchromatic, enlarged nucleus. Morphological changes of pineal gland at rats in the summertime were not as intense as in the winter and finding of the gland in the group II is compatible with those from the control group. Stereological results show both in winter and summer in the first group the decrease of volume density of pinealocytes, their cytoplasm and nuclei and in the second group in winter increase the volume density of pinealocytes, cytoplasm and nuclei, while in the second group the results in summertime are equal to those from the control group. Photoperiodism is modifier of effect of LF-EMF on morphological structure of pineal gland, because the gland recovery is incomplete in winter and reversible in summer.

KEY WORDS: photoperiodism, pineal gland, electromagnetic field, rat

## INTRODUCTION

Electromagnetic radiations, that have been more and more present in human living and working environment in the last decade, represent one of important stress-bearing factors (1). Artificial electromagnetic fields have disrupted natural electrochemical balance in living systems at all levels of organization (2). Most researchers point out that nervous system (3,4,5) and endocrine system (6,7,8,9) are most sensitive to the effect of electromagnetic field. Pineal gland, as a neuroendocrine organ which affects activity of several neuroendocrine structures and non-endocrine systems, is a neuroendocrine transmitter and functions on the border of nervous and endocrine system. When it receives information on the degree of light in the outer environment, the epiphysis transforms vibration of humoral transducers, which then coordinate the rhythm of other function with the rhythm of brightness (10). Para ventricular nucleus of hypothalamus (11) is a link in chain that may maintain photo periodical control of epiphysis. Effect of EMF on pineal gland occupies attention of scientists having in mind that magneto-sensitivity of this organ with vertebrata: fish (12), amphibians (13) and people (14) has been proved. The studies have shown that the production of melatonin, the main hormone of epiphysis, is suppressed by the effect of EMF (15). Melatonin changes different biological processes that participate in regulation of circadian rhythms, seasonal reproduction, sleep, retina physiology, vascular tonus, metabolism, immunity and neoplasm (16). This hormone shows clear antiproliferative properties with defined malignant types of cells (17), and also stimulates different immune parameters that participate in defense mechanisms against tumor (18). Synthetic activity of pineal gland depends on the photoperiod. In the summer period (long days, short nights), the activity of the pineal gland and neuroendocrine sensitivity is increased. In the summer period, its synthetic activity decreases. With most animals such season variations have been found in the function of the pineal gland, and were most tested with hamster (19). The purpose of our study is to determine, using histological and stereological methods, whether photoperiodism has any impact on the effects that chronic (three-month long) exposure to LF-EMF (50Hz) has on morphological characteristics of pineal gland.

## MATERIALS AND METHODS

Experiment was performed on 48 laboratory male rats of Mill Hill strain, out of which 24 animals were exposed to

LF-EMF, while the rest 24 animals were used as control. Conditions of housing and feeding were the same both for control and experimental animals. The study was performed both during summer and winter, following the identical protocol. The animals, starting 24 hours upon their birth until their sexual maturity, were exposed to LF-EMF, 7 hours per day (from 7 a.m. – 14 p.m.) for 5 days a week. After 3 months of exposure to LF-EMF in each season six animals were sacrificed together with control group of animals (group I), while the remaining six experimental and six control rats were sacrificed after three weeks of recovery from exposure to LF-EMF (group II). The EMF was produced with the help of an apparatus made of coil of 2,5 mm thick wire placed on a wooden frame in 1320 turns. The coil was energized from 50Hz, 220V and 16A via auto-transformer, which provides a 60-V output in order to reduce the electric field, so that its value does not exceed 10 V/m at any point of the room in which the experiment was made. With the use of the described apparatus we obtained an inhomogeneous EMF, of decaying intensity from the source (the coil) so that the animals during the exposure time were in the room with different field intensities that ranged from 500µm (measured on the side closer to the coil) to 50µm (measured on the opposite side of the coil). Cages with animals were placed symmetrically on both sides of the coil on the wooden boards with rubber base in order to eliminate mechanical vibrations. After sacrifice of animals through decapitation, pineal glands were fixed in 10% formalin, dehydrated and embedded in paraffin. 4µm paraffin sections were made and stained with haematoxylin-eosin method. Paraffin sections of the gland stained with HE was used for histological and stereological analysis. Stereological analysis was made on every fourth slides of gland stained with HE, using the test system A-144 was placed in the ocular (10x) of a Reichert microscope, with objective 40x magnifications. Selection of the sample was done systematically and intermittently: every second vision field. On analyzed vision field were determine following stereological variables: volume densities of nuclei (V<sub>dn</sub>) and cytoplasm (V<sub>dc</sub>), as well as the volume density of pinealocyte (V<sub>dp</sub>) which is obtained by adding up previous two parameters. The volume density shows which part of the total volume is taken up by the tested phase. It represents a percentage of tested phase (pinealocyte, their cytoplasm or nucleus) in a unit of volume of the pineal gland. Significance of differences of mean values of tested stereological parameters between control and EMF exposed animals was determined using Student's *t*-test.

## RESULTS

Histological analysis of pineal gland in animals that were sacrificed immediately after three months exposure to LF EMF in the winter period shows that its cells are characterized with pronounced polymorphism. Pinealocytes are here densely compressed with unclear inter-cell borders and are of reduced size compared to the control group. It can be noticed that in the peripheral region of the gland of radiated animals, light pinealocytes dominate among which there is much more inter-cell area filled with fibers tissue, unlike the central part which is dominated by dark pinealocytes. Nuclei of these cells are pyknotic and irregular, most frequently of stick-form, while their cytoplasm is of pale color and scarce (Figures 1a and 1b). In pineal glands of animals that were sacrificed in the winter period after three weeks of recovery from three-month exposure to LF-EMF, numerous light vacuolized pinealocytes are noticed, the cytoplasm of which is suppressed into one end of the cell, which gives them a characteristic appearance of ring (Figure 3). With animals sacrificed in summer period, immediately after exposure to LF EMF, the histological finding shows the domination of dark pinealocytes, reduction of their volume as well as hyper chromatic of their nuclei, while the pinealocytes in glands of animals after their three-week recovery, are characterized by a domination of large, light pinealocytes which are, by their characteristics, very similar to pinealocytes in control animals (Figure 4).

### STEREOLOGICAL ANALYSIS OF PINEAL GLAND

Stereological analysis of *volume density of pinealocyte nucleus (Vd<sub>pn</sub>)* in glands of animals sacrificed in the *winter* period in first group showed its significant decrease ( $p < 0,001$ ) in corresponding control group (Table 1). In the second group, i.e. animals that were subjected to three-week recovery from EMF exposure, the volume density of nucleus of pinealocyte (Table 1) is in statistically significant increase ( $p < 0,05$ ) in corresponding control group (Table 1). The results for the *summer* period of the same parameter for the first group, immediately after exposure EMF, show statistically significant decrease ( $p < 0,01$ ) in corresponding control group (Table 1). In the second group, after three-week recovery from EMF, the volume density of nucleus of pinealocyte does not statistically significantly differ from control values. Stereological analysis of *volume density of pinealocyte cytoplasm (Vd<sub>pc</sub>)* in glands of animals sacrificed in

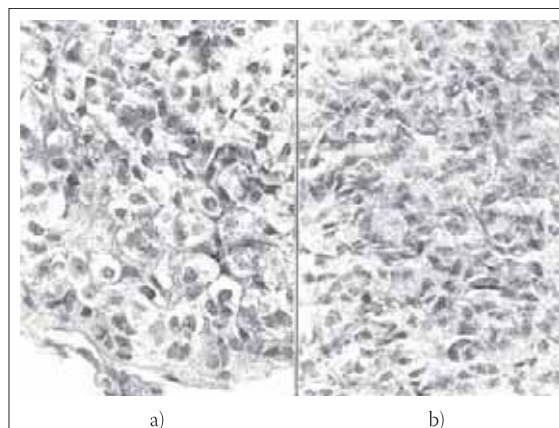


FIGURE 1. Pineal gland in rat: a) control animal b) animal after three-month exposure to LF EMF; HE, oc. 10x, obj. 40x

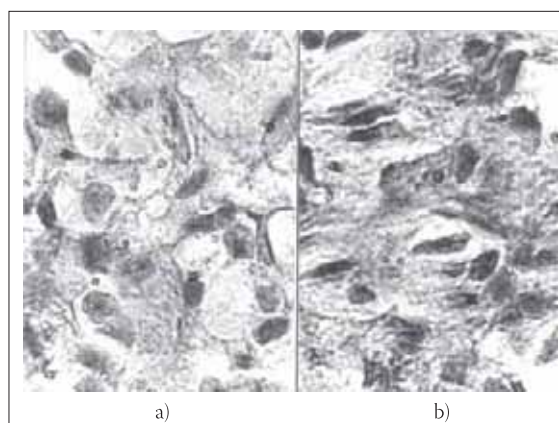


FIGURE 2. Pineal gland in rat: a) control animal; b) animal after three-month exposure to EMF HE, 100 x

*winter* period shows statistically significant decrease ( $p < 0,001$ ) after a three-month EMF exposure. In the second group, after three-week recovery from EMF, statistically significant ( $p < 0,001$ ) increase in volume densities of cytoplasm was noted (Table 2). In *summer* period in first group in glands of animals sacrificed immediately after EMF exposure, there is statistically significant decrease ( $p < 0,001$ ) in volume density of cytoplasm. After three-week EMF recovery, group II, there is an equalization of the value of volume density of cytoplasm with the values noticed in the controls (Table 2). Summarizing two previously determined stereological parameters i.e. values for volume density of nucleus and volume density of pinealocyte cytoplasm, we gained a volume density of these cells (Vdp). Stereological analysis of *volume density of pinealocyte (Vdp)* in glands of animals sacrificed in *winter* period has shown its statistically significant decrease ( $p < 0,01$ ) immediately after a three-

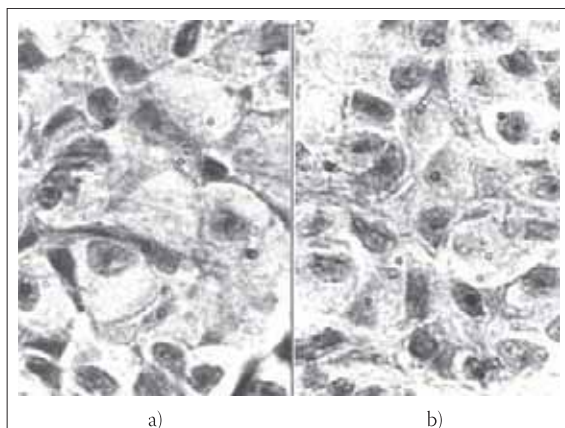


FIGURE 3. Pineal gland in rat: a) control animal; b) animal three months of exposure and three months of recovery HE, 100 x

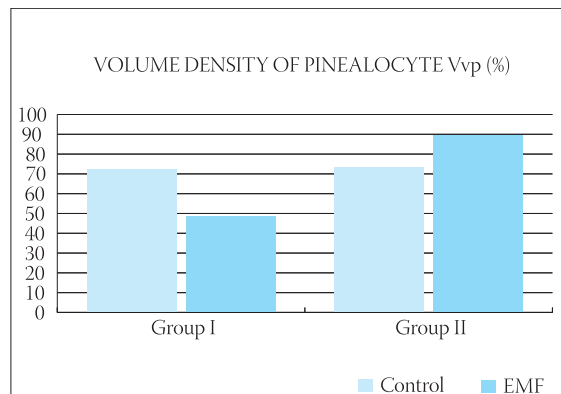


CHART 1. Average values of volume density of pinealocyte (Vdp) in control animals and animals exposed to EMF in **winter** period. Group I: three months after exposure to LF EMF; Group II: after 3 weeks of recovery

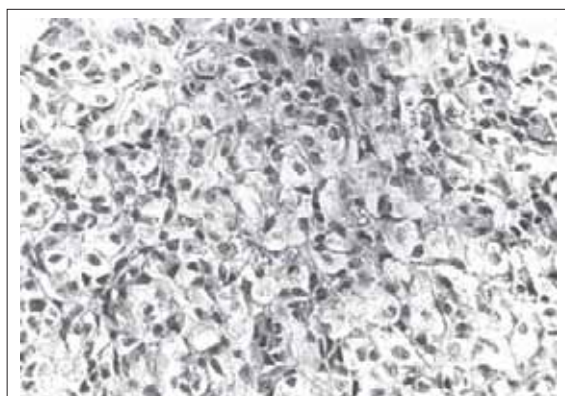


FIGURE 4. Pineal gland in rat: Pineal gland in rat – central part, three months of EMF and three months of recovery, HE, oc. 10 x, l obj. 40 x

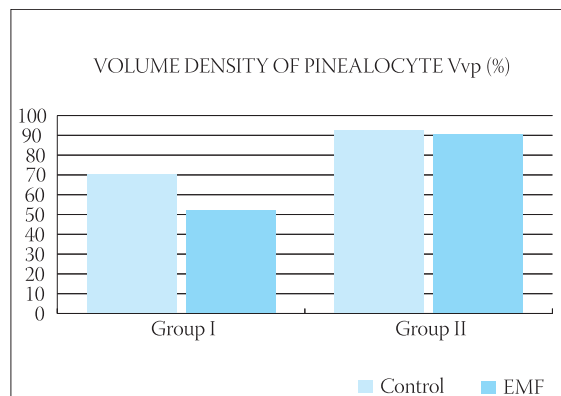


CHART 1. Average values of volume density of pinealocyte (Vdp) of gland of control animals and EMF exposed animals in **summer** period. Group I: 3 months after exposure to LFEMF; Group II: after 3 weeks of recovery

	WINTER Vdnp (%)		SUMMER Vdnp (%)	
	Group I	Group II	Group I	Group II
Control animals	31,77	25,68	30,06	30,14
SE	0,86	1,78	0,38	0,45
EMP animals	19,56 <sup>(1)</sup>	30,99 <sup>(2)</sup>	23,13 <sup>(3)</sup>	28,71 <sup>(4)</sup>
SE	0,79	1,05	1,26	1,15

<sup>(1)</sup> p<0,001; <sup>(2)</sup> p<0,05; <sup>(3)</sup> p<0,01; <sup>(4)</sup> not significant;

TABLE 1. Average value of volume density of nucleus of pinealocyte (Vdnp) per seasons and groups of control animals and animals exposed to LF-EMF in percentages

	WINTER Vdnp (%)		SUMMER Vdnp (%)	
	Group I	Group II	Group I	Group II
Control animals	40,8	47,93	40,16	61,01
SE	3,53	2,39	1,47	0,56
EMP animals	27,55 <sup>(1)</sup>	57,61 <sup>(2)</sup>	28,71 <sup>(3)</sup>	61,44 <sup>(4)</sup>
SE	1,52	1,08	0,89	0,8

<sup>(1)</sup> p<0,01; <sup>(2)</sup> p<0,01; <sup>(3)</sup> p<0,01; <sup>(4)</sup> not significant;

TABLE 2. Average value of volume density of cytoplasm of pinealocyte (Vdcp) per seasons and groups of control animals and animals exposed to LF-EMF in percentages

month EMF exposure, with the average value of 47,11%, and in corresponding control group of 72,58% (Chart 1). In the second group, i.e. animals that were subjected to a three-week recovery from EMF exposure, statistically significant increase in volume density of pinealocyte was noted ( $p < 0,05$ ) amounting to 88,57%, while in the control group it was 72,79%. Stereological analysis of volume density of pinealocyte (Vdp) in glands of animals sacrificed in *summer* period in the first group, showed statistically significant decrease ( $p < 0,01$ ) amounting to 51,83%, while in control group it was 70,23% (Chart 2). After a three-week recovery, the value of this parameter did not significantly differ between the experimental (90,16%) and control (91,16%) groups (Chart 2).

## DISCUSSION

Presented findings of our histological and stereological analyses have shown that a three-month exposure to variable LF-EMF leads to changes of morphology of pineal gland both in winter and summer period. These changes were realized through change of volume of cytoplasm and nucleus of the pinealocytes of animals sacrificed immediately after exposure to LF-EMF. Changes were also registered with animals after three weeks recovery from influence of these fields. Quantification of these results, using stereological analysis as a morphometric method enables an insight in three-dimensional disposition of structural elements of organs and tissues (20). More precisely, a statistically significant **lowering** of the volume density of pinealocyte occurs, the volume density of their nucleus and volume density of their cytoplasm both during winter and summer. However, after a three-week recovery from EMF exposure during winter season, volume density of pinealocytes decreases, while in summer season, after recovery period, volume density was identical to values of this parameter with control animals. Researchers are still looking for the possible place of the cellular interaction with LF-EMF. Many experimental models have indicated that the cell membrane is the primary place of interaction of EMF with living systems, i.e. cells (21). It is assumed that the EMF modified the normal signaling process in the membrane (22) and that the cellular response is consistent with the existence of "biological windows" for individual frequencies, intensity and duration of exposure (3). Biological parameters such as type of the cell, the cell cycle, cell activity, existence of specific growth/mitosis factors, temperature, form of the cell, cell density during EMF exposition (23) present an important interaction factor. There is certain number of researchers (24,25) who be-

lieve that effect of EMF is a specifically stressful situation. It has been shown that LF-EMF induces the expression of the so-called "stress response" protein and that the initiation of transcription of certain genes in the condition of effect of EMF as a stressor could be a mechanism of interaction with cells. These proteins are normally synthesized in cells as a response to physical stress and have a proactive role. Vernhes and co-authors (26) believe that the intensity of the field is the most important for accomplishing of stressful effects of EMF and they have demonstrated that application of the electric field on cell suspension leads to changes in the structure of cell membrane. Exposed to EMF, the permeability of the membrane is increased, which makes possible, according to the expression used by the authors, a free access to cell cytoplasm, i.e. influence of the field on cytoplasmic structural components and biochemical processes that are going on in it. Morphological changes of pineal gland that are found in the second group during winter period may be a result of effect of EMF as stress-bearing factor. Light pinealocytes represent cells that are exhausted through synthetic activity, which could be explained by the production of "stress response" protein. It is possible that such an effect of LF EMF on pineal gland has occurred due to moving of the compensatory gland mechanisms that made possible generating of changes in pathological sense. Namely, according to the theory of functional systems (27), physiological mechanisms that make possible normal activity of animals and humans have been built for millions of years during the evolution development. One of mechanisms enabling normal life activity is a mechanism of self-regulation of physiological functions. This adaptation aspect of the theory of functional systems could be an explanation for the type of found changes on pineal gland in animals during exposure to EMF. In animals that are exposed during a three-month period to LF-EMF in *winter* season, we have found changes in the morphology of the pineal gland even after three weeks of recovery. Pinealocytes are vacuolated and enlarged and the finding coincides with stereological measuring that show **the increase** in volume density of pinealocyte nucleus and their cytoplasm. This indicates that a three weeks recovery in this period was incomplete. Whether vacuolization of cytoplasm is a step toward degeneration of cells or a step toward its recovery would have been possible to see if the experimental protocol had included the groups with longer recovery period. Compensatory mechanisms in the winter period are more disturbed, hence the slower self-regulation of the system. These effects of photoperiods are most probably intermediated by circadian

rhythm of melatonin, because production of melatonin from the epiphysis and its concentration in circulation during night is increased and is directly proportionate to duration of the dark (28). In *summer* period, due to lower neuroendocrine reactivity of pineal gland to the light, morphological changes have reversible character, which means that mechanisms making possible return in the normal state of its structure and function are not damaged. Histological finding, as the stereological analysis of

the pineal gland that was outside the effect of EMF during three weeks, came close to the control group. Results achieved with our experiments indicate effect of photoperiodism as modulator of response of pineal gland to LF-EMF functioning. In order to clearly define mechanisms by which LF EMF impacts the structure and function of the pineal gland, we need further investigations in well defined laboratory conditions of exposure.

## CONCLUSION

- Pineal gland has shown sensitivity to chronic exposure to variable LF EMF. The results of histological and stereological analyses show that after chronic exposure to LF EMF there has been a statistically significant decrease in volume density of pinealocyte, in volume density of its nucleus and volume density of their cytoplasm both in winter and summer periods.
- Photoperiodism is an important modifier of effect of LF EMF on pineal gland because the reaction on chronic exposure is more intensive in winter than in summer.
- Morphological changes of pineal gland after chronic exposure are reversible in summer period while the normal structure of pineal gland is being established after three weeks outside the effect of the field, which was not the case in winter period.

## NON STANDARD ABBREVIATIONS:

- LF-EMF - low frequency electromagnetic field
- EMF - electromagnetic field
- HE - haematoxylin-eosin
- Vdp - volume density of pinealocyte
- Vdnp - volume density of pinealocytes nucleus
- Vdcp - volume density of pinealocytes cytoplasm

## REFERENCES

- (1) Lažetić B. Osnovi magnetobiologije, Medicinski fakultet, Novi Sad, 2004
- (2) Pressman A.S. Elektromagnitnaya signalizacija v zhivoj prirode. Moskva. Sovetskoe radio. 1974; 645
- (3) Berg H. Possibilities and problems of low frequency weak electromagnetic fields in cell biology. *Bioelectrochem. Bioenerg.* 1995; 153-159
- (4) Lukač T., Matavlj A., Rajkovača Z., Rajković V., Kruitskaya G.N., Lažetić B. Effects of the low frequency EMF (50 Hz) on morphological characteristics of brain structure of rats in postnatal period. Proceedings of the Second international conference. Electromagnetic fields and human health. Moscow. 1999; 276
- (5) Cook L.L., Persinger M.A., Koren S.A. Differential effects of low frequency, low intensity (6 mG) nocturnal magnetic fields upon infiltration of mononuclear cells and numbers of mast cells in Lewis rat brains. *Toxicol. Lett.* 2000; 118: 9-19
- (6) Matavlj M., Rajković V., Ušćebrka G., Lukač T., Stevanović D., Lažetić B. Studies on the possible endocrinology effects on 50Hz electromagnetic fields. *J. Occup. Environ. Med.* 2000; 6(2-3): 183-188
- (7) Rajković V., Matavlj M., Gledić D., Lažetić B. Evaluation of rat thyroid gland morphophysiological status after three months exposure to 50 Hz electromagnetic field. *Tissue Cell.* 2003;(35): 223-231
- (8) Ušćebrka G., Žikić D., Lažetić B. Efekat dugotrajnog delovanja elektromagnetskog polja na nadbubrežnu žlezdu pacova. *Ekokonferencija 99. Zaštita životne sredine gradova i prigradskih naselja.* Novi Sad. 1999; pp.:331-336
- (9) Graham C, Cook M.R., Gerkovich M.M., Sastre A Examination of the melatonin hypothesis in women exposed at night to EMF or bright light. *Environ. Health Perspect.* 2001; 109(5): 501-507
- (10) Reiter R. The pineal gland: an intermediary between the environment and the endocrine system. *Psychoneuroendocrinology.* 1983; V.8.P.:31-40
- (11) Pickard G.E., Rutek F.W. The hypothalamic paraventricular nucleus mediates the photoperiodic control of reproduction but not the effect of light on the circadian rhythm of activity. *Neurosci. Lett.* 1983; V. 43.pp.:67-72
- (12) Walker M.W. Learned magnetic field discrimination in yellow fin tuna, *Thunnus albacares*. *J. Comp. Physiol.* 1984; (A) 155: 673-679
- (13) Rodda G. H. The orientation and navigation of juvenile alligator: evidence of magnetic sensitivity. *J. Comp. Physiol.* 1984; A 154:649-658
- (14) Kavaliers M., Ossenkopp K.P., Hirst M. Magnetic field abolish the enhanced nocturnal analgetic response to morphine in mice. *Physiol. Behav.* 1984; 32: 2261-2264
- (15) Selmaoui B., Toitou Y. Sinusoidal 50-Hz magnetic fields depresses rat pineal NAT activity and serum melatonin. Role of duration and intensity of exposure. *Life Sci.* 1995; 57: 1351-1358
- (16) Blask D.E. Melatonin: The pineal gland's anticancer molecule. Proceedings of the Second World congress for electricity and magnetism in biology and medicine, Bologna. 1997;11
- (17) Liburdy R.P. Magnetic fields and breast cancer: Experimental in vitro studies and the melatonin hypothesis. Proceedings of the Second World congress for electricity and magnetism in biology and medicine. Bologna. 1997; 8-9
- (18) Loscher W., Mevissen M., Haubler M. Magnetic fields and breast cancer: Experimental in vivo studies on the melatonin hypothesis. Proceedings of the Second World congress for electricity and magnetism in biology and medicine. Bologna 1997;9
- (19) Matt K.S., Wilson B.W., Morris J.E., Sasser L.B., Miller D.L. and Anderson L. E. The effects of EMP exposure on neuroendocrine mechanisms of environmental integration. Abstract Book of Sixteen annual meeting of the BEMS. Copenhagen. Bioelectromagnetic Society. 1994;49
- (20) Kališnik M. Temelji stereologije. *Acta stereologica* 1985; 4 (Suppl. I): 140-148
- (21) Blank M. Biological effects of environmental electromagnetic fields: molecular mechanisms. *Biosystems* 1995; (3582-3): 175-178
- (22) Lin Y., Nishimura R., Nozaki K., Sasaki N., Kadosawa T., Goto N. et al. Collagen production and maturation at the experimental ligament defect stimulates by pulsing electromagnetic fields in rabbits. *J. Vet. Med. Sci.* 1993; 55 (4): 527-531
- (23) Vernhes M.C., Cabanes P.A., Teissie J. Chinese hamster ovary cells sensitivity to localized electrical stresses. *Bioelectrochem. Bioenerg.* 1999; 48(1):17-25
- (24) Sudakov K.V., Lažetić B., Grujić N. Bases of theory of functional systems –perspectives University of N.Sad, Medical Faculty and P.K. Anokhin Institute of Normal Physiology RAM Moscow, ed. B. Lažetić and K. V. Sudakov, Novi Sad, 1998; pp: 7-16
- (25) Goodman E.M., Greenebaum B., Marron MT. Effects of electromagnetic fields on molecules and cells. *Int. Rev. Cytol.* 1995;158: 279-338
- (26) Luben R. A. Effects of low-energy electromagnetic fields (pulsed and DC) on membrane signal transduction processes in biological systems. *Health Phys.* 1999; 61:15-28
- (27) Liburdy R. P. Cellular studies and interaction mechanisms of extremely low frequency fields. *Radio. Science* 1995; 30: 179-203
- (28) Yellon S.M., Smith J.C., Trong H. Effects of daily 60Hz magnetic field exposure on reproductive development and the melatonin rhythm in the Djungarian hamster sexual maturation 16 BEMS. 1994;49