

CYTOGENETICS FINDINGS AT TURNER SYNDROME AND THEIR CORRELATION WITH CLINICAL FINDINGS

AMRA ČATOVIĆ*

Center for Human Genetics, Medical Faculty, University of Sarajevo,
Čekaluša 90, 71000 Sarajevo, Bosnia and Herzegovina

* Corresponding author

ABSTRACT

Turner Syndrome is a genetic condition in females that results from an abnormal chromosome. One of the X chromosomes is missing or misshapen in the most cells of the body. Three classic clinical symptoms of the syndrome are: incomplete sexual maturation, short stature and pterygium colli. Turner Syndrome is diagnosed by karyotyping. In the retrospective study for a twelve years period (1991-2002) correlation between clinical and cytogenetics findings was established in our Center among 47 examinees from all parts of Federation of Bosnia and Herzegovina, who had suspect clinical diagnosis of Turner Syndrome. The syndrome was demonstrated by cytogenetics examinations in 30(63,8%) examinees and excluded in 17 (36,2%) examinees. The most frequent karyotype is monosomy of X chromosome (45,X) found at 63,3%, than isochromosome of Xq (46,XisoXq) found at 16,7%, mosaic form (46,XX/45,X) and deletion of Xp (46,XdelXp) both at 6,7%, than deletion of Xq (46,XdelXq) and ring of Xp (46,XX/46,XringXp) both at 3,3%. Our results suggest that promptly and exactly diagnosis of Turner syndrome is very important due to introducing growth hormone therapy and estrogen therapy at a very young age.

KEY WORDS: Turner Syndrome, cytogenetics findings, clinical findings

INTRODUCTION

In 1938, at a medical conference, an endocrinologist named Henry Turner described cases of seven young women, aged fifteen to twenty three, with three symptoms: infantilism, congenital webbed neck and cubitus valgus (1). Polani et al. (2) and Wilkins et al. (3) demonstrated that most cases are chromatin-negative, and Ford et al. (4) first described the 45,X karyotype. Turner Syndrome is one of the most common chromosomal abnormalities. It affects approximately 1 in 2,500 live female births (5), corresponding to approximately 1,5 million women worldwide. There appears to be a high fetal wastage with only 1% of these embryos surviving to term (6). Thus, Turner Syndrome is responsible for 7–10% of all spontaneous abortions. Environmental risk factors for conceiving a child with Turner Syndrome are unknown. Turner Syndrome is not, in general, associated with advancing parental age (7). Many physical features are associated with Turner Syndrome: low birth weight and length, webbed neck, low posterior hairline, oedema of the dorsum of the hands and feet in early childhood, short stature (sexual infantilism), puberty failure, ovaries degeneration, primary or secondary amenorrhea, miscellaneous defects (heart – coarctation of the aorta, kidney – horseshoe kidney, eye), and autoimmune pathologies (such as thyroiditis, diabetes mellitus, celiac disease) are frequently observed (8).

Women with Turner Syndrome need long-term follow-up so that early medical intervention may reduce morbidity and improve life expectancy (9,10). Cytogenetics analyses explain etiopathogenesis of Turner Syndrome. Without them clinical diagnosis is uncertain. Cytogenetics findings associated with Turner Syndrome are very different. The number and severity of dysmorphic symptoms depend on these findings (11) (Figure 1). The basic goal of this retrospective study is to evaluate cytogenetic findings in patients with suspect clinical diagnosis of Turner Syndrome and establish correlation between their clinical and cytogenetics findings.

SUBJECTS AND METHODS

The research was done as retrospective study for a twelve years period (1991-2002) and it involved 47 patients who had been send for cytogenetics analyses with diagnosis suspect Turner Syndrome in the “Center for Human Genetics” of Medical Faculty in Sarajevo from all other health institutions throughout the Federation of Bosnia and Herzegovina. Turner Syndrome is diagnosed by a blood test called karyotype. There are several cytogenetics technique used in laboratory: technique of standard, technique of metaphase and prometaphase banding. Prometaphase (high resolution) banding technique ensures better quality of cytogenetics analyses (12). The nucleus of a female cell in interphase has one dark-

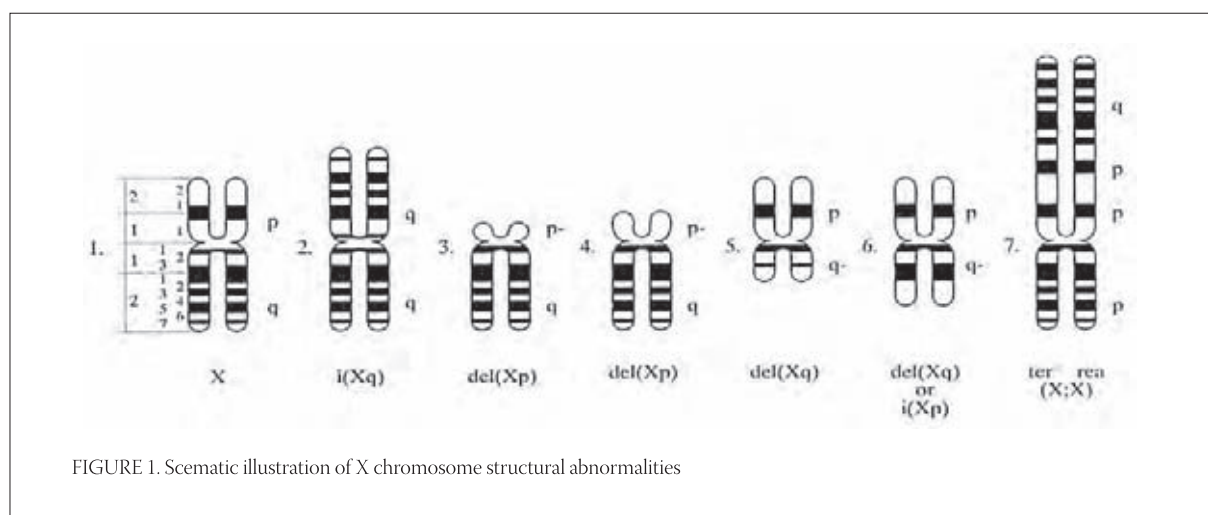


FIGURE 1. Schematic illustration of X chromosome structural abnormalities

1. Normal X chromosome
2. Isochromosome Xq (long arm)
3. Short arm deletion of an X chromosome (Xp-)
4. Interstitial deletion of short arm
5. Interstitial deletion of long arm
6. Long arm deletion of an X chromosome is hard to distinguish from isochromosome Xp because bands are almost identical
7. "End to end" rearrangements Xp

PERIOD OF RESEARCH (1991-2002)	CYTOGENETIC FINDINGS					
	DEMONSTRATED TURNER SYNDROME		EXCLUDED TURNER SYNDROME		TOTAL	
	N ^o	%	N ^o	%	N ^o	%
ALL EXAMINEES	30	63,8	17	36,2	47	100,0

TABLE 1. Correlation of cytogenetics findings with diagnosis suspect Turner Syndrome (1991-2002)

staining X chromosome called Barr body (named after its discoverer, Murray Barr, Canadian researcher, who noticed these dark bodies in 1949 in nerve cell of female cats). Females with karyotype 45,X have none Barr body. Persons with abnormal numbers of X chromosomes have one fewer Barr body than they have X chromosomes per cell. Structural changes of X chromosome are manifested with misshapen Barr bodies (13).

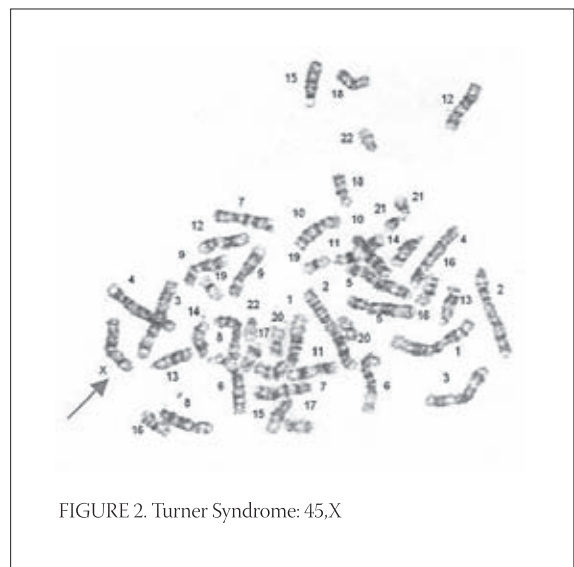
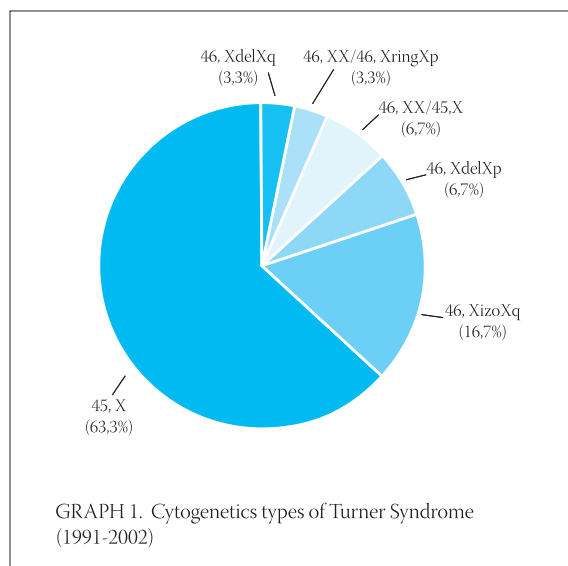
RESULTS

The syndrome was demonstrated by cytogenetics examinations in 30(63,8%) of 47 examinees and excluded in 17 (36,2%) examinees (Table 1). The results of research of correlation between cytogenetics findings examinees with diagnosis suspect Turner Syndrome in a twelve years period (1991-2002) were tested by χ^2 test. Demonstration-excluding Turner Syndrome is on the level of significance $p < 0,05$. Cytogenetics types of Turner Syndrome are shown in Graph 1. The most frequent karyotype is monosomy of X chromosome (45,X - Figure 2) found at 63,3%, than isochromosome of Xq (46,XisoXq - Figure 3) found at 16,7%, mosaic form (46,XX/45,X) and deletion of Xp (46,XdelXp - Figure 4) both at 6,7%, than deletion of Xq (46,XdelXq) and ring of Xp (46,XX/46,XringXp) both at 3,3%. The results of research of frequency of cytogenetics types

of Turner Syndrome in a twelve years period (1991-2002) were tested by χ^2 test and level of significance is $p < 0,05$.

DISCUSSION

The distinction between male and female, found in most species of animals and plants, is based on the type of gametes (ova, spermatozoa) produced by individual. Gonadal development in human is determined by presence of the XX (female) or the XY (male) genotype. Combined cytogenetic, fluorescence in situ hybridization (FISH), and molecular analysis are useful in the diagnosis of sex chromosome aberrations (14). Turner Syndrome is a genetic condition in females that results from an abnormal chromosome. One of the X chromosomes is missing or misshapen in the most cells of the body. For normal development and function of ovary, two X chromosomes are necessary. Second X chromosome is necessary for ovarian maintenance, but not for its differentiation. Without that second X chromosome, ovaries, which are developed at the beginning, finally degenerate. Girls with several of the characteristic features may be suspected during infancy or early childhood. If a female adolescent does not begin puberty at a normal age she should be evaluated for Turner Syndrome. As early diagnosis has several potential advantages



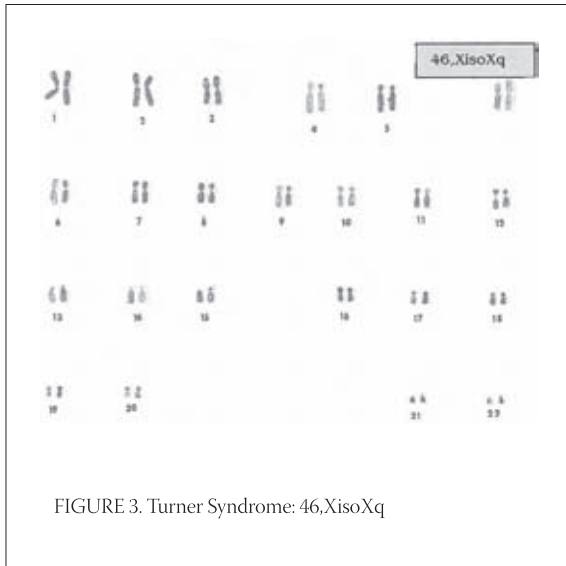


FIGURE 3. Turner Syndrome: 46,XisoXq

a cytogenetic analysis should be considered in all girls with unexplained short stature (15). Turner Syndrome is diagnosed by karyotyping. There is a correlation between the exact cytogenetic appearance and the phenotype in Turner Syndrome. The most frequent karyotype (16), at 48% of all cases, is X monosomy (45,X). In our sample percentage is higher (63,3%), which can be in connection with the value of sample (smaller sample). They appear to be more severely affected clinically than other forms of the disorders. Structural cardiac and renal abnormalities occur more frequently in this group. Monosomy X results from nondisjunction as a result of failure of the sex chromatids to separate during meiosis in the parental gamete or in the early embryonic divisions. The latter usually results in mosaicism. According to Elsheikh et al. (16), about 11% of Turner patients are mosaic with both 45,X and 46,XX cell

lines. In our sample percentage is lower. We found that 6,7% study patients were mosaic. The two population of cells may appear in every tissue of the body or only in certain ones. Presumptive evidence for mosaics lies in a discrepancy between sex chromatin pattern and karyotype, or through observing a low percentage of chromatin-positive nuclei (5-15%) in phenotypic females. The clinical spectrum of 45,X/46,XX mosaicism is wide and may vary from cases quite typical of Turner Syndrome with many associated anomalies to cases with normal gonads and normal stature. Difference in clinical patterns may be related to the time of X chromosome loss and the particular tissues involved. Rare karyotype 46,XX is possible with one X chromosome with changed structure. Structural X chromosome abnormalities are thought to occur as a result of breakages in the X chromosome with subsequent reunion of X chromosome sequences. These changes can be more or less visible. Isochromosome Xq is the most common structural abnormality. About 18% (16) of patients having Turner Syndrome have an isochromosome Xq, i.e., replication of long arm of the late replicating X chromosome. This findings is very similar to our results (16,7%). The Barr body are larger than normal. They exhibit many of stigmata of 45,X Turner Syndrome, i.e. short stature and sexual infantilism, but are less likely to have pterygium colli and aortic coarctation. In this group risk of autoimmunity, particularly thyroiditis and deafness is increased. In study of Elsheikh et al. (16) types 46,XXp-, 46,XXq- and 46,XXr together comprise no more than 14,5% of Turner Syndrome. In our study the percent of these karyotypes is very similar (13,3%). Barr bodies in these cases are smaller than normal. These cases are with variable phenotype

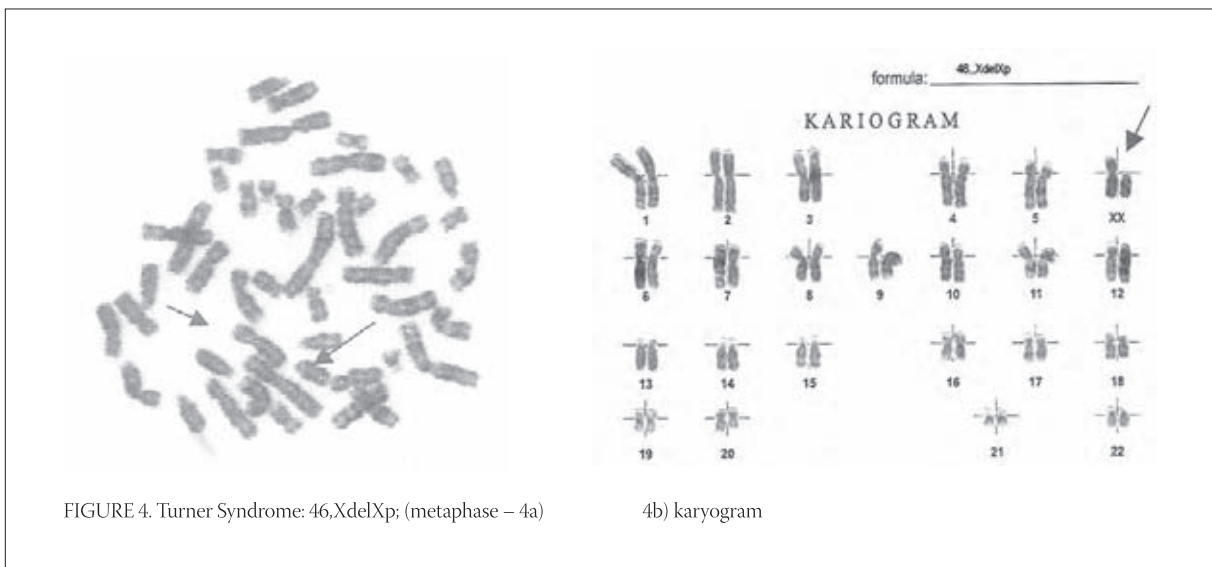


FIGURE 4. Turner Syndrome: 46,XdelXp; (metaphase – 4a)

according to the amount of deletion of both short and long arms. Medical care of Turner patients is planning on the base of cytogenetic and clinical findings. Special

attention is given to possible infertility treatment in later life and future motherhood of these women (17,18).

CONCLUSION

In retrospective study for a twelve years period (1991-2002) it was done the evaluations of cytogenetics analyses of patients with diagnosis suspected Turner Syndrome who were send in the "Center for Human Genetics" of Medical Faculty in Sarajevo from all other health institutions throughout the Federation of Bosnia and Herzegovina. The syndrome was demonstrated by cytogenetics examinations in 30(63,8%) examinees and excluded in 17 (36,2%) examinees. The most frequent karyotype is monosomy of X chromosome (45,X) found at 63,3%, than isochromosome of Xq (46,XisoXq) found at 16,7%, mosaic form (46,XX/45,X) and deletion of Xp (46,XdelXp) both at 6,7%, than deletion of Xq (46,XdelXq) and ring of Xp (46,XX/46,XringXp) both at 3,3%. It is very important that females with Turner Syndrome are diagnosed promptly so they may have the opportunity to receive growth hormone therapy and estrogen therapy at a very young age.

REFERENCES

- (1) Turner H.H. A syndrome of infantilism, congenital webbed neck and cubitus valgus. *Endocrinology*, 1938; 23:566-574.
- (2) Polani P.E., Hunter W.F., Lennox B. Chromosomal sex in Turner syndrome with coarctation of the aorta. *Lancet*, 1954; 2:120-121.
- (3) Wilkins L., Grumbach M., Van Wyk J. Chromosome sex in „ovarian dysgenesis.“ *J. Clin. Endocrinol.*, 1954; 14:1270-1271.
- (4) Ford C.E., Jones K., Polani P., de Almeida J., Briggs J. A sex chromosome anomaly in a case of gonadal dysgenesis (Turner Syndrome). *Lancet*, 1959; 1: 711-713.
- (5) Lippe B. Turner syndrome. *Endocrinol. Metab. Clin. North. Am.*, 1991; 20:121-152.
- (6) Stratakis C.A., Rennert O.M. Turner syndrome: molecular and cytogenetics, dysmorphology, endocrine, and other clinical manifestations and their management. *Endocrinologist*, 1994; 4:442-453.
- (7) Jacobs P., Dalton P., James R., Mosse K., Power M., Robinson D., Skuse D. Turner syndrome: a cytogenetic and molecular study. *Ann. Hum. Genet.*, 1997; 61:471-483.
- (8) Bonamico M., Pasquino A.M., Mariani P., Danesi H.M., Culasso F., Mazzanti L., Petri A., Bona G; Italian society of pediatric gastroenterology hepatology; Italian study group for Turner syndrome. Prevalence and clinical picture of celiac disease in Turner syndrome. *J. Clin. Endocrinol. Metab.*, 2002; 87(12):5495-5498.
- (9) Quigley C.A., Crowe B.J., Angelin D.G., Chipman J.J. Growth hormone and low dose estrogen in Turner syndrome: results of a United States multi-center trial to near-final height. *J. Clin. Endocrinol. Metab.*, 2002; 87(5): 2003-2041.
- (10) Saenger P., Wikland K.A., Conway G.S., Davenport M., Gravholt C.H., Hintz R., Hovatta O., Hultcrantz M., Landin-Wilhelmsen K., Lin A., Lippe B., Pasquino A.M., Ranke M.B., Rosenfeld R., Silberbach M. Recommendations for the diagnosis and management of Turner syndrome. *J. Clin. Endocrinol. Metab.*, 2001; 86:3061-3069.
- (11) Zergollern Lj., i sur. *Medicinska genetika 2*. Ed. Školska knjiga, Zagreb, 1994; pp.:42-47.
- (12) www.slh.edu/cytogenetics [access: 27.07.2005.]
- (13) Tamarin R.H. *Principles of Genetics*. 7th edition, WCB McGraw-Hill, 2002; pp:195-196.
- (14) Petković I., Barišić I., Bago R. Cytogenetic evaluation, fluorescence in situ hybridization, and molecular study of psu idic(X)(pter-->q22.3::q22.3-->pter) chromosome aberration in a girl with moderate growth retardation. *Croat. Med. J.* 2003; 44(4):494-499.
- (15) Massa G., Verlinde F., De Schepper J., Thomas M., Bourguignon J.P., Craen M., de Zegher F., Francois I., Du Caju M., Maes M., Heinrichs C.; Belgian study group for paediatric endocrinology. Trends in age at diagnosis of Turner Syndrome. *Arch. Dis. Child.* 2005; 90(3):267-268.
- (16) Elsheikh M., Dunger D.B., Conway G.S., Wass J.A. Turner's Syndrome in adulthood. *Endocr. Rev.*, 2002; 23 (1):120-140.
- (17) Hreinsson J.G., Ojala M., Fridström M., Borgström B., Rasmussen C., Lundqvist M., Tuuri T., Simberg N., Mikkola M., Dunkel L., Hovatta O. Follicles are found in the ovaries of adolescent girls with Turner's syndrome. *J. Clin. Endocrinol. Metab.*, 2002; 87(8): 3618-3623.
- (18) Waelkens J.J. [Turner Syndrome in mother and daughter]. *Ned. Tijdschr. Geneesk.*, 2004, 148(24):1208-1210.